



***Candida lusitaniae* Endophthalmitis: A Brief Literature Review with a Focus on Treatment Options**

Hamadullah Shaikh, MD ¹, Devin Weber, MD ¹, Jordan Hamburger, MD ¹ and Chairut Vareechon, PhD ¹

¹ Thomas Jefferson University Hospital, Philadelphia, PA 19107, USA

* Corresponding author: hamadullahs@gmail.com

Submitted: 2 August 2022, accepted: 13 September 2022, published: 31 December 2022

Keywords: *Candida lusitaniae*; Endophthalmitis

How to cite: Shaikh, H.; Weber, D.; Hamburger, J.; Vareechon, C. *Candida lusitaniae* Endophthalmitis: A Brief Literature Review with a Focus on Treatment Options. *Priv. Pract. Infect. Dis.*, 2022, 2(4): 13; doi:[10.55636/ppid2040013](https://doi.org/10.55636/ppid2040013).

© 2022 Copyright by Authors. Licensed as an open access article using a [CC BY 4.0](https://creativecommons.org/licenses/by/4.0/) license.



Introduction

Intraocular fungal infections are uncommon. They may originate either exogenously, as occurs with penetrating trauma and postoperative infections, or endogenously, through hematogenous spread. Patients at the highest risk of endogenous endophthalmitis are those with central venous catheters, total parenteral nutrition, and active intravenous drug use, as well as those who are immunosuppressed [1]. *Candida* species are the most common fungi identified from endogenous sources related to the above. Although the incidence of ocular involvement is unclear, a few studies provide a range of 2.2–16% in patients with candidemia [2,3]. Non-albicans species of *Candida* infections are very rare. In particular, *C. lusitaniae* is found in only approximately 1% of patients with *Candida* blood stream infections [4]. Treating *Candida* ophthalmologic infections usually requires expertise of both ophthalmology and infectious diseases. Patients who have evidence of only chorioretinitis should be treated with systemic antifungal agents. Intravitreal injection in combination with systemic antifungals is recommended for patients with infections involving the macula or vitreous humor. Vitrectomy along with intravitreal injection and systemic antibiotic therapy is needed for patients with heavy vitritis [5]. The duration of treatment is decided on a case-by-case basis but typically consists of four to six weeks of systemic antifungal therapy.

Case

The patient is a 32-year-old male with a past medical history of intravenous (IV) drug use and a recently diagnosed methicillin-resistant *Staphylococcus aureus* right calf abscess who presented with a two-week history of left eye pain. He denied any kind of external trauma or surgical procedures to his left eye and was not a contact lens wearer. His initial symptom was pain that worsened over time. He then developed progressive vision loss along with sensitivity to light. He reported intermittent fevers and chills since the onset of his eye pain. At the time of presentation, he was not taking any antibiotics for his right calf abscess.

On arrival, his vital signs included a temperature of 99.5 degrees Fahrenheit, a heart rate of 97 beats/minute, a blood pressure of 136/77, and a respiratory rate of 18, and oxygen saturation was 98% at room temperature. His initial comprehensive metabolic exam revealed hyponatremia with a sodium level of 132 mmol/L (normal- 135–146), and the rest of the electrolyte and liver function tests were within normal limits. His complete blood count revealed anemia with a hemoglobin level of 10.9 (normal: 14–17 g/dL) and thrombocytosis with a platelet count of 459,000 (normal: 140–400 B/L), but his white blood count was within a normal range with 75% differential neutrophils. Upon initial examination through ophthalmology, he exhibited the presence of more than 20 white blood cells with 1 mm hypopyon in the anterior chamber and moderate-to-severe vitreous opacities in B scan ultrasonography but no evidence of retinal detachment. The examination of his right eye failed to reveal any abnormalities. These findings were highly suspicious for endogenous endophthalmitis in a patient actively using IV drugs. Ophthalmology obtained intravitreal cultures and provided local treatment with 0.1 mL intravitreal vancomycin, 0.1 mL ceftazidime and 0.1 mL voriconazole.

Given the suspicion for a systemic infection, two sets of blood cultures were drawn, and he was then started on broad-spectrum antibiotics, including vancomycin 1 g Q12H and piperacillin/tazobactam 3.375 g Q8H. He was also screened for HIV, Hepatitis B and C, given his IV drug abuse history. We also ordered a transthoracic echocardiogram (TTE) that showed no evidence of vegetations; however, he did have evidence of mildly thickened aortic valve leaflets. An aerobic bottle from one of the two sets of blood cultures drawn on admission was positive with a time to positivity (TTP) of 38 h using our BD BACTEC FX instrument. Gram stain (Figure 1) demonstrated yeast. Vancomycin and Piperacillin/Tazobactam were stopped, and he was started empirically on Anidulafungin pending further work up and identification of the yeast. This yeast was eventually identified as *Candida lusitanae* through matrix-assisted laser desorption/ionization-time of flight (MALDI-TOF). Vitreous fluid cultures and repeat blood cultures remained negative. Given the prolonged duration of the symptoms and thickened aortic valve leaflets in the TTE along with the high-risk history of our patient, we opted for a transesophageal echocardiogram (TEE), which was negative for vegetations. His vision improved over time, and there was resolution of hypopyon upon repeat ophthalmologic examination with stable vitreous opacities. He was eventually discharged on 400 mg oral fluconazole daily for a total of 4 weeks based on the susceptibility data provided by our microbiology lab (Table 1). He was given instructions to follow up with us and ophthalmology, but unfortunately was lost to follow up. However, he re-presented to our institution 3 months later with symptoms of opioid withdrawal and did not have any visual complaints at that time.

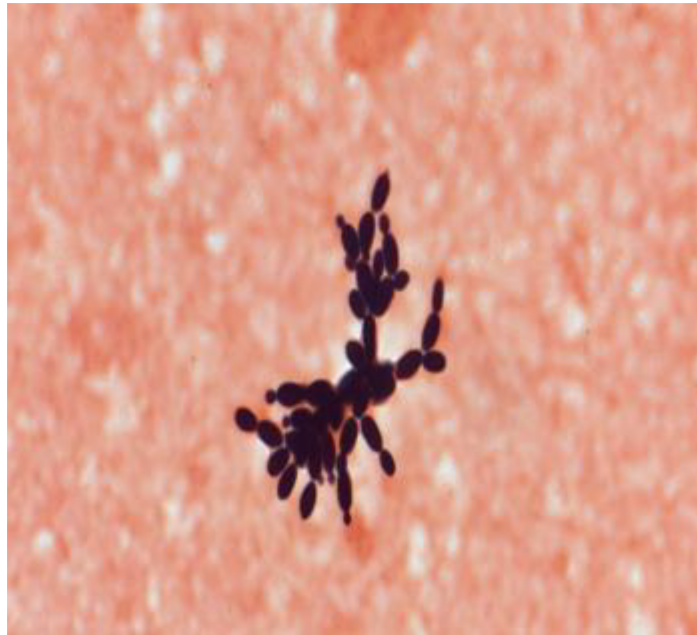


Figure 1: Gram stain from our patient.

Table 1: *Candida lusitanae* MIC values for our patient.

Antibiotic	MIC
Amphotericin B	0.5 mcg/mL
Anidulafungin	0.25 mcg/mL
Caspofungin acetate	0.5 mcg/mL
Fluconazole	0.5 mcg/mL
Flucytosine	<0.06 mcg/mL
Itraconazole	0.12 mcg/mL
Micafungin	0.06 mcg/mL
Posaconazole	0.03 mcg/mL
Voriconazole	<0.008 mcg/mL

Discussion

We report a case of endogenous endophthalmitis secondary to *C. lusitanae fungemia*. He was re-admitted to our center 3 months later for a different problem and did not report any ocular complaints at that time. Yamamoto and colleagues described a case of a 69-year-old patient on immunomodulators with bilateral endophthalmitis due to *C. lusitanae fungemia* successfully treated with 42 days of systemic antifungal therapy without intravitreal antibiotic injections, the majority of which consisted of systemic fluconazole and is the only other case report describing endophthalmitis due to *C. lusitanae* to the best of our knowledge [6].

Candida endophthalmitis is an important complication of candidemia and most commonly occurs due to *C. albicans* [3,7]. The incidence of ocular involvement is unclear, with a few studies providing

a range of 2.2–16% in patients with candidemia [2,3], with chorioretinitis being more common than endophthalmitis [3]. Another study evaluating 118 patients with candidemia found 9% of patients to have chorioretinitis, and none had endophthalmitis [8].

The identification of candida species is important in choosing the appropriate antifungal therapy. *C. lusitaniae* can often be resistant to amphotericin B, either intrinsically [9] or can develop resistance to amphotericin B, along with the acquisition of cross-resistance to fluconazole and echinocandins during therapy [10,11].

Clinical breakpoints have not been devised for *C. lusitaniae* by the Clinical and Laboratory Standards Institute (CLSI). However, CLSI does provide us with epidemiological cut-off values [12], which are 2 µg/mL for amphotericin B and 1 µg/mL for fluconazole and anidulafungin. Given these data and comparing them with our patients isolates MIC values, we were reassured that a combination of anidulafungin and fluconazole was likely to provide our patient with a favorable outcome, and this was evidenced by the sterilization of blood cultures and the improvement in his vision.

The optimal agent to treat intraocular candidiasis mainly depends on whether or not the antifungal agent has adequate penetration in the ocular compartments. In general, the intraocular penetration of echinocandins and amphotericin B, either in conventional or liposomal form, is poor [13].

Of all the azole antifungals available, most clinical experience available to date is with fluconazole [14]. Experimental data in rabbits show that it is able to achieve levels as high as 50% of its peak plasma levels in the vitreous [13], with greater penetration in inflamed ocular tissues than non-inflamed tissues [15]. Data in humans suggest that levels as high as 70% of total plasma levels can be achieved in the vitreous with systemic administration [16]. Owing to its excellent intraocular penetration, favorable safety profile, excellent response rates and abovementioned reasons, it has become a preferred agent in the treatment of candida endophthalmitis.

Another azole that has risen to fame in the treatment of intraocular candidiasis is voriconazole. Some of the advantages of using voriconazole include a broader spectrum of activity to include molds [14,17], against fluconazole-resistant candida species, e.g., *C. krusei* [14] and a high bioavailability that enables it to attain intraocular levels that are well above the MIC90 of most organisms implicated in causing fungal endophthalmitis [17,18]; however, further studies are needed to establish its role in the treatment of candida ophthalmologic infections.

Fungal endophthalmitis is an ophthalmologic emergency that needs to be treated aggressively. The duration of treatment is not well established. A strategy that is laid out by the Infectious Diseases Society of America (IDSA) [4] is to treat the condition for 4–6 weeks and repeat an eye exam before the discontinuation of the anti-fungal agent. Whether or not to use intravitreal agents remains debatable. However, in the IDSA guideline document [4], they recommend including intravitreal agents as part of treatment in patients with macular involvement, with amphotericin B and voriconazole being the options available to us at this time. In conclusion, we describe a rare and the second ever case of *C. lusitaniae* endophthalmitis reported in the literature to the best of our knowledge that was successfully treated with a 4-week course of systemic fluconazole through an initial one-time intravitreal administration of voriconazole.

Author Contributions: H.S.: Wrote majority of the case report and contributed the most to literature search; D.W.: Proof read the case report and made necessary changes; C.V.: Reviewed microbiological data and provided references for the treatment part of the case; J.H.: Wrote the abstract of the case report. All authors have read and agreed to the published version of the manuscript.

Funding: The case report has no external funding.

Conflicts of Interest: The authors declare no conflict of interest.

References

1. Orasch, C.; Marchetti, O.; Garbino, J.; Schrenzel, J.; Zimmerli, S.; Mühlethaler, K.; Pfyffer, G.; Ruef, C.; Fehr, J.; Zbinden, R.; et al. Candida species distribution and antifungal susceptibility testing according to European Committee on Antimicrobial Susceptibility Testing and new vs. old Clinical and Laboratory Standards Institute clinical breakpoints: A 6-year prospective candidaemia survey from the fungal infection network of Switzerland. *Clin. Microbiol. Infect.* **2014**, *20*, 698–705. [[CrossRef](#)] [[PubMed](#)]
2. Kannangara, S.; Shindler, D.; Kunimoto, D.Y.; Sell, B.; DeSimone, J.A. Candidemia complicated by endophthalmitis: A prospective analysis. *Eur. J. Clin. Microbiol. Infect. Dis.* **2007**, *26*, 839–841. [[CrossRef](#)] [[PubMed](#)]
3. Oude Lashof, A.M.; Rothova, A.; Sobel, J.D.; Ruhnke, M.; Pappas, P.G.; Viscoli, C.; Schlamm, H.T.; Oborska, I.T.; Rex, J.H.; Jan Kullberg, B. Ocular Manifestations of Candidemia. *Clin. Infect. Dis.* **2011**, *53*, 262–268. [[CrossRef](#)] [[PubMed](#)]
4. Pappas, P.G.; Kauffman, C.A.; Andes, D.R.; Clancy, C.J.; Marr, K.A.; Ostrosky-Zeichner, L.; Reboli, A.C.; Schuster, M.G.; Vazquez, J.A.; Walsh, T.J.; et al. Clinical Practice Guideline for the Management of Candidiasis: 2016 Update by the Infectious Diseases Society of America. *Clin. Infect. Dis.* **2016**, *62*, e1–e50. [[CrossRef](#)] [[PubMed](#)]
5. Riddell, J., IV; Comer, G.M.; Kauffman, C.A. Treatment of Endogenous Fungal Endophthalmitis: Focus on New Antifungal Agents. *Clin. Infect. Dis.* **2011**, *52*, 648–653. [[CrossRef](#)] [[PubMed](#)]
6. Yamamoto, S.; Ikeda, M.; Fujimoto, F.; Okamoto, K.; Wakabayashi, Y.; Sato, T.; Tatsuno, K.; Kaburaki, T.; Yoshida, S.; Okugawa, S.; Koike, K.; Moriya, K. Bilateral Candida endophthalmitis accompanying Candida lusitanae bloodstream infection: A case report. *J. Infect. Chemother.* **2018**, *24*, 147–149. [[CrossRef](#)] [[PubMed](#)]
7. Nagao, M.; Saito, T.; Doi, S.; Hotta, G.; Yamamoto, M.; Matsumura, Y.; Matsushima, A.; Ito, Y.; Takakura, S.; Ichiyama, S. Clinical characteristics and risk factors of ocular candidiasis. *Diagn. Microbiol. Infect. Dis.* **2012**, *73*, 149–152. [[CrossRef](#)] [[PubMed](#)]
8. Donahue, S.P.; Greven, C.M.; Zuravleff, J.J.; Eller, A.W.; Nguyen, M.H.; Peacock, J.E., Jr.; Wagener, M.W.; Yu, V.L. Intraocular candidiasis in patients with candidemia. Clinical implications derived from a prospective multicenter study. *Ophthalmology* **1994**, *101*, 1302–1309. [[CrossRef](#)] [[PubMed](#)]
9. Guinet, R.; Chanas, J.; Goullier, A.; Bonnefoy, G.; Ambroise-Thomas, P. Fatal septicemia due to amphotericin B-resistant Candida lusitanae. *J. Clin. Microbiol.* **1983**, *18*, 443–444. [[CrossRef](#)] [[PubMed](#)]
10. Favel, A.; Michel-Nguyen, A.; Peyron, F.; Martin, C.; Thomachot, L.; Datry, A.; Bouchara, J.; Challier, S.; Noël, T.; Chastin, C.; Regli, P. Colony morphology switching of Candida lusitanae and acquisition of multidrug resistance during treatment of a renal infection in a newborn: Case report and review of the literature. *Diagn. Microbiol. Infect. Dis.* **2003**, *47*, 331–339. [[CrossRef](#)] [[PubMed](#)]
11. Asner, S.A.; Giulieri, S.; Diezi, M.; Marchetti, O.; Sanglard, D. Acquired Multidrug Antifungal Resistance in Candida lusitanae during Therapy. *Antimicrob Agents Chemother.* **2015**, *59*, 7715–7722. [[CrossRef](#)] [[PubMed](#)]
12. CLSI. *Epidemiological Cutoff Values for Antifungal Susceptibility Testing*, 3rd ed.; CLSI supplement M59; Clinical and Laboratory Standards Institute: Wayne, PA, USA, 2020.
13. Tod, M.; Lortholary, O.; Padoin, C.; Chaine, G. Intravitreal penetration of fluconazole during endophthalmitis. *Clin. Microbiol. Infect.* **1997**, *3*, 379A. [[CrossRef](#)] [[PubMed](#)]
14. Walsh, T.J.; Foulds, G.; Pizzo, P.A. Pharmacokinetics and tissue penetration of fluconazole in rabbits. *Antimicrob. Agents Chemother.* **1989**, *33*, 467–469. [[CrossRef](#)] [[PubMed](#)]
15. Breit, S.M.; Hariprasad, S.M.; Mieler, W.F.; Shah, G.K.; Mills, M.D.; Grand, M.G. Management of endogenous fungal endophthalmitis with voriconazole and caspofungin. *Am. J. Ophthalmol.* **2005**, *139*, 135–140. [[CrossRef](#)] [[PubMed](#)]
16. Urbak, S.F.; Degn, T. Fluconazole in the management of fungal ocular infections. *Ophthalmologica* **1994**, *208*, 147–156. [[CrossRef](#)] [[PubMed](#)]
17. Hariprasad, S.M.; Mieler, W.F.; Holz, E.R.; Gao, H.; Kim, J.E.; Chi, J.; Prince, R.A. Determination of vitreous, aqueous, and plasma concentration of orally administered voriconazole in humans. *Arch. Ophthalmol.* **2004**, *122*, 42–47. [[CrossRef](#)] [[PubMed](#)]
18. Gao, H.; Pennesi, M.E.; Shah, K.; Qiao, X.; Hariprasad, S.M.; Mieler, W.F.; Wu, S.M.; Holz, E.R. Intravitreal voriconazole: An electroretinographic and histopathologic study. *Arch. Ophthalmol.* **2004**, *122*, 1687–1692, Erratum in *Arch. Ophthalmol.* **2005**, *123*, 130. [[CrossRef](#)] [[PubMed](#)]